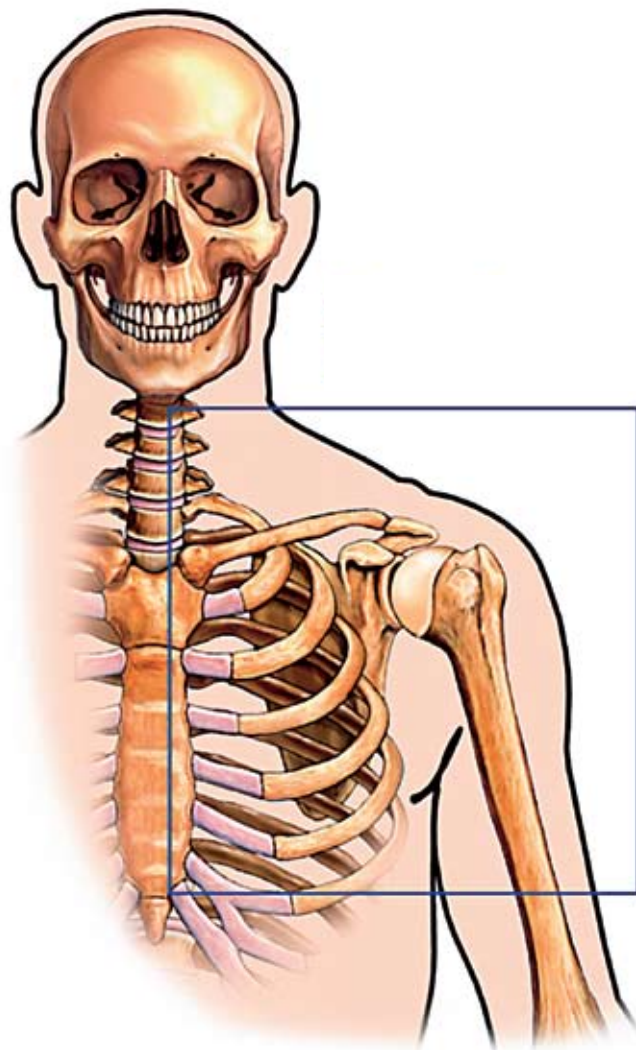


Exploring shoulder pain



John Gibbons BSc (OST) explains how to diagnose and treat shoulder pain in its many forms

When it comes to dealing with shoulder pain, many physical therapists commonly treat where the client presents with pain, rather than considering if this is the actual cause of the problem or merely a symptom. Here, I will focus on the role of the rotator cuff during motion of the gleno-humeral joint and discuss three case studies that involve pain and/or stiffness during abduction in the frontal plane. When clients present with symptoms to the shoulder joint, the majority of their signs and symptoms will have either a loss of motion or a presenting pattern of pain at some stage of abduction, i.e. between 0-180 degrees.

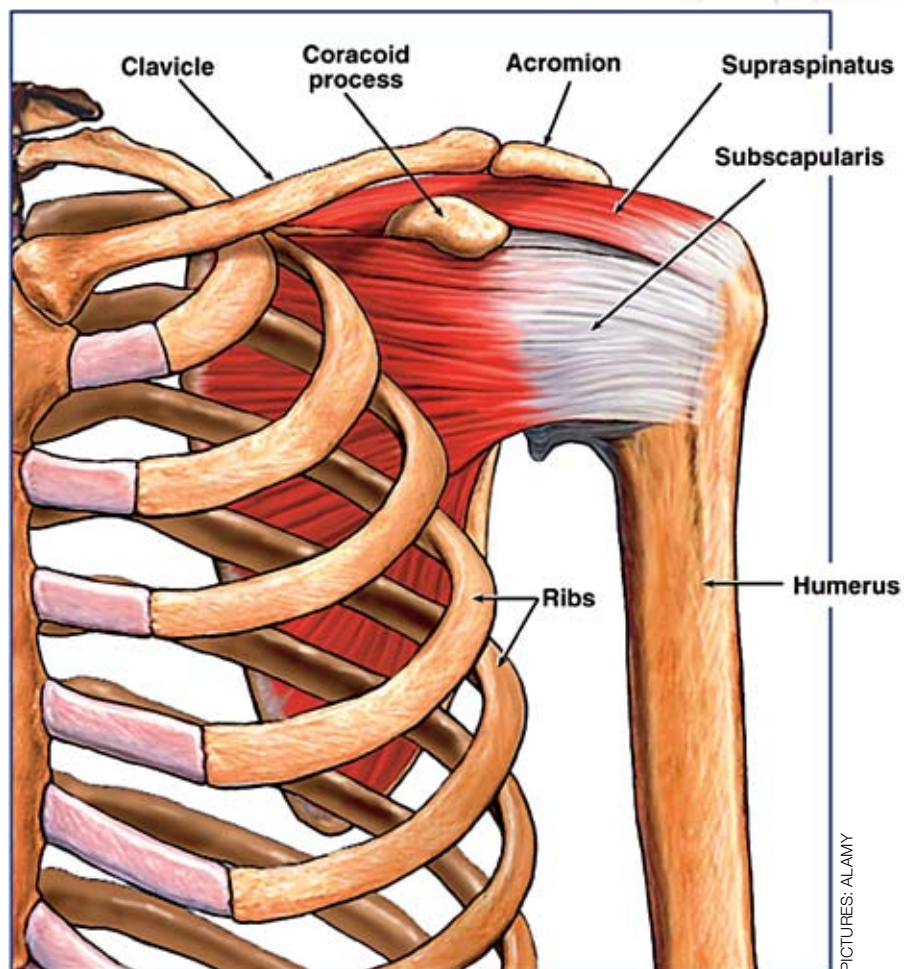
We have to be cautious when our clients have presenting pain that is located to the shoulder and upper limb area as it could be referred from a multitude of areas, for example the cervical spine or visceral (diaphragm, gall bladder, liver, lungs, etc).

Clients will tell you that it hurts in the arm, but might have difficulty pinpointing the precise area. An important question to ask is 'do you have night pain?'. If the answer's yes, the next question should be 'can you reduce your symptoms by altering your position?'. If the answer's no, we can consider this a red flag and refer the client on to the medical profession.

The rotator cuff

Commonly called the SITS muscle group, or active ligaments, the rotator cuff comprises the supraspinatus, infraspinatus, teres minor and subscapularis. Abducting the arm requires the integration of the gleno-humeral joint, scapulo-thoracic articulation, acromio-clavicular joint (ACJ) and the sterno-clavicular joint (SCJ). If any of these joints don't behave properly dysfunction will occur.

Before we look at the function of the rotator cuff



PICTURES: ALAMY

during abduction, I would like to talk about scapulo-humeral rhythm. This states that when the humerus abducts, the scapula will rotate at a 2:1 ratio. For example, at 90 degrees of abduction the humerus would have abducted 60 degrees and the scapula would have rotated 30 degrees.

The initiation of abduction for approximately the first 20 degrees is by the supraspinatus, then the middle fibres of the deltoid take over. At 30 degrees the scapula will start to rotate laterally by the contraction of the upper and lower trapezius and the serratus anterior. There will come a point during abduction, generally between 60 and 90 degrees, when the greater tuberosity approximates the acromion process. This will potentially compress the soft tissue structures within the sub-acromial space and cause an impingement.

To prevent this, the infraspinatus and teres minor laterally rotate the humerus while abducting. As the humerus continues abducting, the subscapularis and supraspinatus have an adducting effect that pulls the humeral head deep into the glenoid fossa to prevent impingement and provide stability. The reverse will happen on the movement of adduction. This motion has to incorporate the above-mentioned joints, i.e. the ACJ, SCJ and the muscle balance of the specific rotator cuff/scapula muscles, etc.

A simple active motion of abduction can help the sports therapist gather information about the nature and site of the injury. If we understand the functional anatomy of the movement, our clinical reasoning with regards to a diagnosis of the client's pain will be a lot clearer. The following examples are case studies who have presented at my clinic.

Case study 1

History

This client is a 75-year-old male with an inability to abduct the gleno-humeral joint for the first 20 degrees, with an appearance of a reverse scapulo-humeral rhythm. He fell off a ladder onto his right shoulder three weeks before his appointment at the clinic and sustained superficial bruising, which has since healed. His GP referred him to the clinic with a suspected frozen shoulder.

Examination

First observations point to the possibility of adhesive capsulitis (frozen shoulder), but this can quickly be assessed by one of two tests. If you ask the client to externally rotate the humerus there will be a capsular pattern, i.e. a restriction to the rotation with some pain, normally near the deltoid tuberosity. The second test is for the therapist to passively abduct the arm. If the movement is possible and pain-free, a 'joint' restrictive problem can be ruled out.

Hypothesis

The tests prove the client doesn't have a capsular pattern as I am able to passively abduct his arm with no restriction or pain. This tells me the integrity of the joint is okay and his problem is due to soft tissue. What the client is unable to do is initiate abduction and it is the supraspinatus that is partly responsible for this movement. I consider that the client has a full thickness tear of his supraspinatus. (He later has a MRI scan, which confirms this.)

Treatment/management

The difficulty for this client is that he's 75 and a surgeon wouldn't want to operate on his shoulder. His treatment plan therefore focuses on maintaining the mobility of the shoulder and its associated areas.

Case study 2

History

This is a 34-year-old female painter and decorator who has pain between 70 and 110 degrees of abduction. The pain is located towards the insertion of the deltoid muscle at the deltoid tuberosity. Her symptoms started three days previously while painting a high ceiling. There is some history of shoulder pain, but this only seems to be aggravated by painting ceilings or when the arm works at around 90 degrees of abduction.

Hypothesis

The client's pain is located between a specific range of movement, which can be referred to as a painful arc. Her history suggests there is some impingement, but what? There is a choice of soft tissue structures that could be getting trapped – the supraspinatus, subacromial bursa, infraspinatus and biceps long head, to name a few. When a client has a painful arc the supraspinatus or the bursa is often a potential causative structure.

Examination

As the active range of movement (ROM) is painful, and the passive ROM causes no symptoms, we know a contractile tissue is implicated and we can rule out the involvement of the joint. A hypothesis of supraspinatus tendonitis is therefore a possible diagnosis. In theory, it is sometimes difficult to specify an individual muscle of the rotator cuff, so the term rotator cuff tendinopathy is a common diagnosis.

Empty can test (or supraspinatus impingement)

The patient abducts the shoulder to 90 degrees then horizontally flexes to 30 degrees.



They are then asked to 'empty' (tip) their imaginary can.



The same test is applied with overpressure.

Treatment/management

Some sports therapists would treat the inflamed supraspinatus by performing a friction technique, which I believe would cause further irritation to an already compromised structure. In my experience, if you change the position of the gleno-humeral joint this will have a major effect on the client's pain. We can change the position of the joint by looking at lengthening the pectoralis minor and activating the middle/lower fibres of the trapezius and rhomboids.

Case study 3

History

This is a 25-year-old rugby player who has pain on the superior aspect of his right shoulder near the distal end of his clavicle and the junction to the acromion. Pain is exacerbated at the end range of abduction (180 degrees) and horizontal flexion. He trains twice a week and has a game at the weekend. The injury occurred a week previously while training – he remembers being tackled and landing on his right side. He felt pain and had to come off the pitch. He applied ice to the area four times over the next two days and took anti-inflammatories to ease the pain. He has mentioned a 'bump' on the top of his shoulder since the injury occurred.

Examination

The only movement that seems to cause discomfort is the end range of abduction and horizontal flexion. This is made worse by passive testing with overpressure at the end range. There is a noticeable bump on top of the right shoulder and localised tenderness to palpation over this area. There is no referring and the cervical spine shows no involvement when tested.

Sport | Shoulder pain

Hypothesis

The site of the injury is at the acromio-clavicular joint (ACJ), as the pain is localised and a bump has appeared. The client has probably sustained a grade two sprain of this joint, which could be confirmed on x-ray. Ideally the client would hold a weight in their hand while being x-rayed to see how much separation is present to the joint. The difficulty with this joint is that it will not realign itself due to the overstretching of the AC ligaments.

A common test to confirm or deny this hypothesis is the scarf test. This range of motion performed by the client is simply a movement of horizontal flexion. If the therapist applies an overpressure from this position it often causes an increase in pain.

Scarf test



Ask the client to place their hand onto the opposite shoulder. If pain or restriction is present, this would indicate a dysfunction with the right ACJ.

Treatment/management

Out of all the joints in the body, the AC joint is one I can't manipulate back into position due to the laxity of the ligaments. Consequently, the treatment has to focus on mobility of the whole shoulder girdle and joint. Rugby players can be advised to wear extra padding or try a form of taping to help prevent the injury getting worse.

In conclusion

It can be seen from these case studies that one specific movement performed by the client in the frontal plane (abduction) can help us hypothesise which tissues are causing the pain. However, as I have mentioned earlier, we should not 'chase' the presenting pain of the patient, but look to identify the possible source/cause of their symptoms. The case studies were different in their prognosis, but had one similar trait – pain/restriction during abduction.



John Gibbons BSc (OST) is a sports osteopath/therapist and lecturer in sports medicine at the University of Oxford and St Mary's University. John is a regular speaker at FHT

Sports Conferences. Tel: 07850 176600, email: j.gibbons@peaksport.co.uk or visit www.peaksport.co.uk



1



2



3


Strengthening the shoulder

Exercises 1-3 (shown above)

Pictured are some advanced exercises that help to stabilise the scapula while activating the inner core muscles. Research has shown that the stronger the core muscles, the more stable the shoulder complex.

Exercise 4 (shown on right)

This exercise can be used to help stabilise the shoulder joint using one of the myofascial slings (posterior oblique).



4